

Treatment Methods for Different Variations Syndrome Mirizzi



Omarov N.B.¹, Aimagambetov M. Zh.², Abdrakhmanov S.T.³, Auenov M.A.⁴, Lazarev A.K.⁵, Akparov T.L.⁶, Akhmetzhanova D.O.⁷

^{1,2,3,4,5,6,7}Department of Hospital Surgery, NJSC "MUS", Semey, Republic of Kazakhstan

ABSTRACT: The number of patients with complicated forms of cholelithiasis of cholelithiasis is progressively growing. One of the complications of gallstone disease is Mirizzi syndrome (SM). The reason for the development of which is the spread of the inflammatory - destructive process from the gallbladder to the bile ducts with the formation of pressure ulcers in the common bile duct, as a result of which the formation of a cholecystobiliary fistula occurs, through which stones from the gallbladder enter the main bile ducts

The analysis of the surgical treatment of patients with cholelithiasis (GSD) treated in the UH NJSC "MUS" was carried out. There were 3842 patients in total, Patients were in the period from January 2012. to July 2018 The analysis revealed that of all these patients with gallstones, Mirizzi SM type III and IV syndrome was diagnosed in 25 (0.7%). In 14 (56%) patients with type III SM and type IV SM, 11 (44%). The main group consisted of 10 (40%) patients and 15 (60%) patients included in the control group. The main group completed:

1) In type III SM (only 4 (40%) patients). One patient underwent hepaticojejunostomy according to the clinic method (2017/0423.1). In 3 patients, cholecystohepaticocholedochoplasty was performed with U-shaped interrupted sutures on the drainage according to Vishnevsky (2017 / 0980.1);

2) In type IV SM (a total of 6 (60%) patients). 4 patients underwent hepaticojejunostomy according to the clinic method (2017/0423.1). In 2 patients, cholecystohepaticocholedochoplasty was performed with U-shaped interrupted sutures on the drainage according to Vishnevsky (2017 / 0980.1).

The developed and tested methods of surgical treatment of Mirizzi syndrome of types III and IV make it possible to improve the immediate and long-term results of surgical treatment of patients with this pathology.

These methods of surgical treatment allow preserving the physiology of the bile outflow without postoperative complications typical for traditional hepaticojejunostomy (incompetence of the anastomotic sutures, stricture of hepaticojejunostomy).

KEYWORDS: Complications of cholecystectomy, Mirizzi syndrome, acute calculous cholecystitis, acute calculous cholecystitis and overweight, surgical treatment, cholecystectomy by mini-access, hepatic choledochojejunostomy, cholecystohepatic choledochoplasty.

INTRODUCTION

The number of patients with complicated forms of cholelithiasis is progressively growing [1,2,10]. One of the complications of gallstone disease is Mirizzi syndrome (SM). The reason for the development of which is the spread of the inflammatory - destructive process from the gallbladder to the bile ducts with the formation of pressure ulcers in the common bile duct, resulting in the formation of a cholecystobiliary fistula, through which stones from the gallbladder enter the main bile ducts [1,3,4,12]. Among patients who underwent cholecystectomy, Mirizzi syndrome occurs in 1–5% of cases [5]. Before surgery, SM is detected only in 12.5–22% of cases [6]. In honor of the Argentine surgeon Pablo Mirizzi was named "Mirizzi Syndrome" was named. This surgeon in 1948, during intraoperative cholangiography, did not find stones in the bile duct in the presence of its contracture in combination with bile stasis. Of all the proposed, the most commonly used classification proposed by A. Csendes (1989):

1) in type I - from the neck of the gallbladder or cystic duct, calculus, compresses the common hepatic duct;

Treatment Methods for Different Variations Syndrome Mirizzi

2) in type II - a cholecysto-choledocheal fistula is formed, capturing less than 1/3 of the circumference of the common hepatic duct;

3) in type III - a cholecysto-choledocheal fistula is formed, extending to 2/3 of the circumference of the common hepatic duct;

4) in type IV - there is a cholecysto-choledocheal fistula with wall destruction along the entire circumference of the common hepatic duct.

For the diagnosis of SM, ultrasound of the hepatobiliary region is used as a screening method of research. Ultrasound is the most accessible and safest non-invasive diagnostic method, however, it is possible to suspect SM using ultrasound only in 4 - 46% of cases [7]. According to many authors, endoscopic retrograde cholangiopancreatography (ERCP) is considered a more effective method of verification. In relation to this pathology, ERCP has a sensitivity equal to 62-75% [8,9,11]. Among the disadvantages of this method, it is necessary to note the risk of injury and a high risk of complications, such as pancreatitis, mechanical damage to the biliary tract and duodenum, bleeding. Recently, magnetic resonance cholangiopancreatography (MRCP) is gaining popularity, since it is a highly informative, but at the same time, non-invasive diagnostic method.

Objective: To improve the results of surgical treatment in various types of Mirizzi Syndrome III and IV.

RESEARCH METHODS

We have analyzed the surgical treatment of patients with cholelithiasis (GSD) treated in the UG NAO "MUS". There were 3842 patients in total, Patients were in the period from January 2012. to July 2018 The analysis revealed that of all these patients with gallstones, Mirizzi SM type III and IV syndrome was diagnosed in 25 (0.7%). In 14 (56%) patients with type III CM and type IV CM, 11 (44%).

The ratio of men and women was 6 (24%) and 19 (76%), respectively. The age of the patients ranged from 41 to 83 years, with an average of 62 years. Of the constitutional characteristics, 14 (56%) patients were overweight: 7- grade I obesity, 5- grade II obesity, 2- grade III obesity.

Patients with SM were admitted with a clinical picture of acute calculous cholecystitis and a picture of obstructive jaundice. There were 3 (12%) patients with mild jaundice, 8 (32%) with moderate jaundice, 14 (56%) patients with severe jaundice.

All patients were operated on. From online accesses:

- 1) upper midline laparotomy in 5 (20%) patients;
- 2) from mini - access by mini - assistant apparatus "Liga - 7" - in 4 (16%);
- 3) a universal retractor developed in the clinic (RK patent No. 90060) - in 9 (36%);
- 4) mini-access using the modernized "Universal retractor for patients with overweight" - 7 (28%) (Figure 1-2).

The patients were divided into 2 groups depending on the method of performing the operation.

RESULTS

15 (60%) patients were included in the control group. He underwent intraoperative cholangiography followed by cholecystectomy. Type III SM was diagnosed in 10 (66.7%) patients. In 4 (40%) of them, the operation was completed by uncoupling the cholecysto-duodenal fistula. These patients underwent removal of calculus from the common bile duct and drainage of the common bile duct through a fistulous defect according to Keru. In 6 (60%) patients underwent hepaticojejunostomy with an interintestinal anastomosis according to Brown and a plug according to Shalimov. Patients with type IV CM 5 (33.3%) underwent hepaticojejunostomy on an isolated loop of the jejunum according to Roux and drainage according to Felker. In 3 patients (60%), hepaticojejunostomy was performed on a frame drainage. With inter-intestinal anastomosis according to Brown, plug according to Shalimov in 2 (40%) patients. Of these, 9 (60%) patients were hospitalized without acute clinical symptoms in a planned manner.

The main group consisted of 10 (40%) patients, these patients underwent cholecystectomy, intraoperative cholangiography (RK patent No. 90500), fibrocholedochoscopy using a conductor developed in the clinic through the fistulous opening. These patients had acute symptoms of cholecystitis and were hospitalized on an emergency basis. This group has completed: 1) In type III CM (only 4 (40%) patients). One patient underwent hepaticojejunostomy according to the clinic method (2017/0423.1). In 3 patients, cholecystohepaticocholedochoplasty was performed with U-shaped interrupted sutures on the drainage according to Vishnevsky (2017 / 0980.1); 2) In type IV SM (a total of 6 (60%) patients). 4 patients underwent hepaticojejunostomy according

Treatment Methods for Different Variations Syndrome Mirizzi

to the clinic method (2017/0423.1). In 2 patients, cholecystohepaticocholedochoplasty was performed with U-shaped interrupted sutures on the drainage according to Vishnevsky (2017 / 0980.1).

Complications were observed in the control group - 15 patients who were operated on with the traditional laparotomic approach: postoperative wound seroma - in 2 (13.3%), bile leakage (after hepaticojejunostomy with interintestinal anastomosis according to Brown) - in 1 (6.7%) patient. 6 months after the removal of the T-shaped drainage according to Keruu, one patient developed a hepaticoholedochus stricture, which a month later underwent hepaticojejunostomy according to the clinic method. 2 (13.3%) patients died. In one case, the cause of death was hepatic-renal failure against a background of severe intoxication and purulent cholangitis (on the 2nd day after the operation), and in the second case, the disseminated intravascular coagulation syndrome (on the 2nd day after the operation).

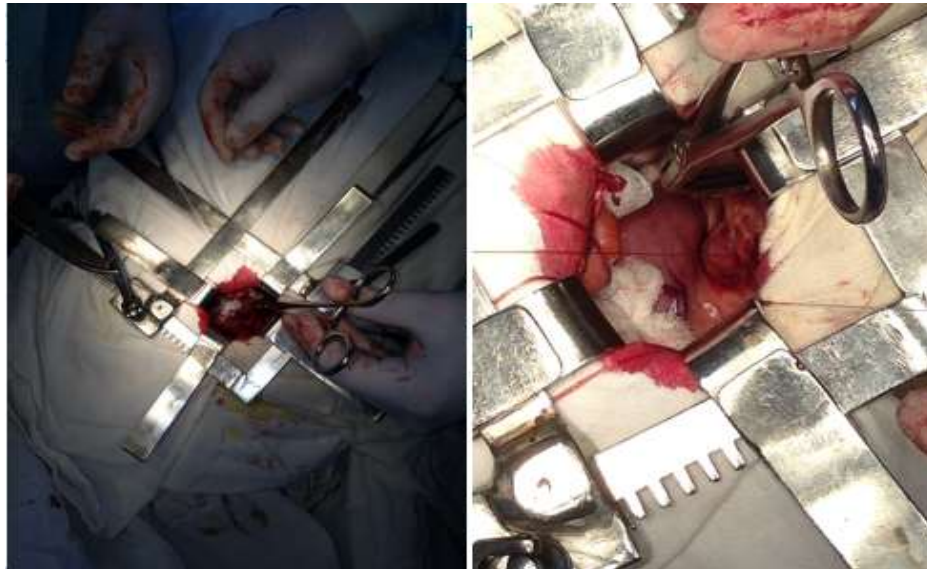


Figure 1-2. Universal retractor for overweight and obese patients, type of surgery

In the main group, in 6 patients who underwent cholecystohepaticocholedochoplasty, postoperative fistulocholangiography was performed on the 7th day, during which the contrast freely entered the duodenum, there was no suture leakage and no narrowing of the anastomosis. The Vishnevsky drainage tube from the common bile duct was removed on the 9th - 12th day. In the main group of patients who underwent hepaticojejunostomy according to the clinic method, there were no postoperative complications or deaths.

We have filed an application for the Eurasian patent "Universal retractor for overweight and obese patients" EAPO registration number No.201900402 dated 10.07.2019 (Figure 1-2).

Overweight patients with cholecystoduodenal fistula underwent surgical treatment with the use of the "Universal retractor for overweight patients" developed by us and the new "Method of dissociation of the cholecystoduodenal fistula followed by cholecystectomy in obese patients from the mini-access." An application was filed for ROSSPATENT "Method of dissociation of the cholecystoduodenal fistula followed by cholecystectomy in obese patients from the mini-access" registration number "Federal Institute of Industrial Property" (FIPS) of the Russian Federation No. 2019107425/20 (014452) dated 03/14/2019.

DISCUSSION

Due to the many difficult situations and emerging problems arising in the process of surgical treatment, forces the surgical community to discuss in various surgical forums. This raises a lot of questions and requires the development of ways to eliminate them. And we offer the results of our research to solve the problem of this disease. The method of elimination of the wall defect of hepaticoholedochus developed by us can be one of the methods of choice for surgical treatment of patients with cholelithiasis complicated by Mirizzi's type III and IV syndrome.

There are no conflicts of interest in this study.

CONCLUSIONS

- 1) The developed and tested methods of surgical treatment of Mirizzi syndrome of types III and IV can improve the immediate and long-term results of surgical treatment of patients with this pathology.

Treatment Methods for Different Variations Syndrome Mirizzi

2) These methods of surgical treatment allow maintaining the physiology of the bile outflow without postoperative complications characteristic of traditional hepaticojejunostomy (incompetence of the anastomotic sutures, stricture of hepaticojejunostomy).

REFERENCES

- 1) Egorova E.A., Makarova D.V., Bazhin A.V., Kalimulina D.S., Nikonorenko A.M., Loshkarev D.Ye. Possibilities of radiation methods in the diagnosis of complicated forms of cholecystitis (literature review and clinical observations) // Radiology-practice. 2016. No. 5. S.26-41.
- 2) Kokhanenko N. Yu. Et al. The choice of surgical tactics in patients with Mirizzi syndrome using MRI diagnostics // Bulletin of St. Petersburg University. Series 11. Medicine, 2014. No. 2.
- 3) Akbarov M.M., Kurbaniyazov Z.B., Rakhmanov K.E. Improvement of surgical treatment of patients with fresh injuries of the main bile ducts. 2014. No. 4. S. 39-44.
- 4) Postrellov N.A., Shishkin A.A., Lodygin A.V. Clinical and anatomical assessment of Mirizzi syndrome // Experimental and Clinical Gastroenterology. 2015. No. 9. S. 52-58
- 5) Galperin, E.I. Mirizzi syndrome: features of diagnosis and treatment // Annals of Surgical Hepatology. - 2006. - No. 3. - S. 7-10.
- 6) Brekhov E.I., Brykov I.V., Aksenov I.V., Andrianov G.A. Laparoscopic cholecystectomy and correction of some of its complications // Kremlin Medicine. Clinical Bulletin. - 2000. - No. 2. - P. 13-16
- 7) Siplivy VA, Evtushenko DV, Petrenko GD, Andreeshchev SA, Evtushenko AV Diagnostics and surgical treatment of Mirizzi syndrome. Clinical practice. - 2016. - No. 8. - S. 8-11.
- 8) Kulezneva Yu.V., Plyusnin B.I., Lyuosev S.V. et al. Modern technologies in the diagnosis and treatment of Mirizzi syndrome // Ros. honey. messenger. - 2008. - T 13, No. 4. - S. 61-66.
- 9) Styazhkina S.N., Valinurov A.A., Shabardin A.M., Ayupov A.I. Results of the analysis of the peculiarities of diagnostics and surgical treatment of acute and chronic calculous cholecystitis // Electronic scientific and educational bulletin "Health and education in the XXI century." 2016. Vol. 18. No. 2. S. 129-131.
- 10) Augustin T., Moslim M.A., Brethauer S., Aminian A., Kroh M., Schneider E., Walsh R.M. Obesity and its implications for morbidity and mortality after cholecystectomy: A matched NSQIP analysis // Am J Surg. 2017. No. 213 (3). R.539-543.
- 11) Lee J.Y., Keane M.G., Pereira S. Diagnosis and treatment of gallstone disease // Practitioner. 2015. No. 259 (1783). R.15-92.
- 12) Schirmer B.D., Winters K.L., Edlich R.F. Cholelithiasis and cholecystitis // J Long Term Eff Med Implants. 2005. No. 15 (3). R.329-338.
- 13) 16. Vorobey A.V., Orlovsky Y.N., Vizhinis E.I., Shuleyko A.C. Surgical Treatment of Biliobiliary and Biliodigestive Fistulas. Annaly khirurgicheskoy gepatologii = Annals of HPB surgery. 2016; 21 (3): 92-100.
- 14) 17. Yetişir F, Zarer AE, Acar HZ, et al. Laparoscopic resection of cholecystocolic fistula and subtotal cholecystectomy by tri-staple in a Type V Mirizzi Syndrome. Case Reports Hepatol 2016.